

Thrombocytopenia Possibly Induced by Pregabalin

Pregabalin, which was released in Canada in 2005, may be used in the treatment of neuropathic pain, postherpetic neuralgia, partial-onset seizures, and fibromyalgia. To our knowledge, this is the first reported case of pregabalin-induced thrombocytopenia.

CASE REPORT

A 91-year-old woman was admitted to hospital with a 5-day history of nonproductive cough and shortness of breath.* Her previous medical history included peptic ulcer disease, and her concurrent medical conditions were osteoarthritis, osteoporosis, gastroesophageal reflux disease, and chronic obstructive pulmonary disease (COPD). The platelet count 18 months before the admission was $278 \times 10^9/L$ (normal range $150 \times 10^9/L$ to $400 \times 10^9/L$).

Medications before admission included omeprazole 20 mg daily, calcium carbonate 500 mg daily, vitamin D 400 units daily, celecoxib 100 mg once or twice daily, etidronate 400 mg daily for 14 days followed by calcium carbonate 500 mg daily for 76 days, fluticasone 125 µg and salmeterol 50 µg (combined) by inhaler 1 or 2 puffs twice daily, and acetaminophen 325–650 mg daily. The only change to the patient's medication regimen in the past 5 years had been the initiation of pregabalin 50 mg once daily for osteoarthritis, 3 months before presentation. The only over-the-counter product that the patient had taken recently was a single 400-mg dose of ibuprofen 3 days before admission. The patient denied use of herbal medications. The patient did not drink alcohol and had no known drug allergies.

Physical examination showed a frail elderly female. A respiratory examination revealed shortness of breath with bilateral wheezes. Chest radiography showed bibasilar atelectasis. Vital signs were as follows: blood pressure 128/90 mm Hg, heart rate 105 beats/min, respiratory rate 24 breaths/min, temperature 36.4°C, and oxygen saturation 93% on room air. The results of neurologic, cardiovascular, and musculoskeletal examinations were unremarkable. Abdominal examination did not suggest splenomegaly. There was no evidence of bruising or bleeding.

Complete blood count on admission revealed hemoglobin 159 g/L (normal range 120 to 160 g/L), hematocrit 0.47 (normal range 0.36 to 0.48), mean corpuscular volume 88 fL (normal range 82 to 100 fL), platelet count $23 \times 10^9/L$, and white blood cell count $7.2 \times 10^9/L$ (normal range $4 \times 10^9/L$ to $11 \times 10^9/L$). The serum creatinine level was 177 µmol/L (normal range 35 to 100 µmol/L). Examination of a peripheral blood smear revealed normocytic and normochromic red blood cells, with neutrophils showing slight toxic changes. The celecoxib and pregabalin were discontinued.

On day 2 of the hospital stay, the patient experienced retrosternal chest pain; she became very short of breath and anxious. The respiratory rate had increased to 60 breaths/min, and she required oxygen (4 L/min) to maintain an oxygen saturation of 90%. Blood pressure was 140/86 mm Hg, heart rate 132 beats/min, and temperature 36.6°C; the white blood cell count had increased to $14.5 \times 10^9/L$ and the platelet count to $82 \times 10^9/L$. Electrocardiography showed no ischemic changes, and the

chest pain was not relieved by sublingual nitroglycerin. She received salbutamol 5 mg and ipratropium 500 µg (combined) by nebulizer and morphine 2 mg IV, which reduced the dyspnea and chest pain. Ceftriaxone 1 g IV daily was initiated for possible exacerbation of COPD.

The hematology department was asked to investigate the thrombocytopenia. Further work-up revealed no antinuclear antibody, rheumatoid factor 10 kU/L (normal range 0 to 20 kU/L), C-reactive protein 69.9 mg/L (normal range 0 to 8 mg/L), and lactate dehydrogenase 288 U/L (normal range 100 to 235 U/L); serum protein electrophoresis yielded normal results.

On day 3, the patient described symptoms of a urinary tract infection. Urinalysis revealed more than 30 white blood cells per high-power field (normal range 0 to 5); the urine tested positive for nitrites, but the results of urine culture were negative. There was no change to the antibiotic regimen, as ceftriaxone would cover common urinary pathogens. On day 5 the patient was still wheezing and short of breath, and prednisone 30 mg daily was prescribed. On day 9 the ceftriaxone was discontinued, and on day 10 the prednisone was discontinued. At that point, the patient no longer required oxygen, and the oxygen saturation was 92% on room air. The patient was discharged with a platelet count of $473 \times 10^9/L$ (Figure 1).

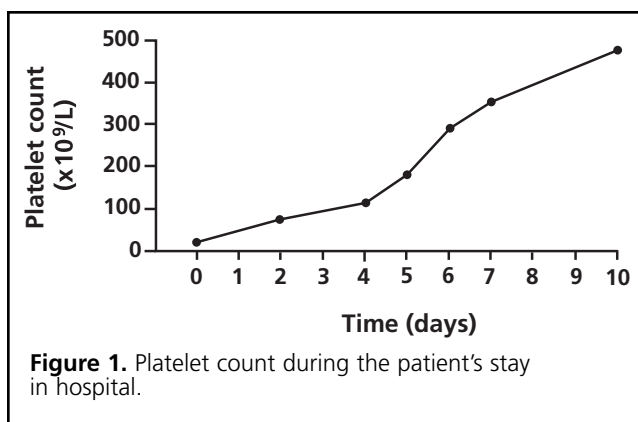
DISCUSSION

The annual incidence of drug-induced thrombocytopenia is estimated at 10 cases per million population.¹ Generally, the platelet count falls 7 or more days after starting a new drug and recovers rapidly, within 1 to 10 days of discontinuation.^{1,2} In clinical trials, 3% of patients receiving pregabalin and 2% of those receiving placebo experienced a decrease in platelet count, defined as less than 20% of baseline or less than $150 \times 10^9/L$.³ Patients treated with pregabalin experienced a mean decrease in platelet count of $20 \times 10^9/L$; the decrease was $11 \times 10^9/L$ for patients receiving placebo. One patient experienced severe thrombocytopenia, with a platelet count of less than $20 \times 10^9/L$. Application of the Naranjo probability scale⁴ to the case reported here suggests a probable relation between the pregabalin and the thrombocytopenia.

A search of MEDLINE, EMBASE, International Pharmaceutical Abstracts, and Reactions Weekly (for January 1950 to June 2008) with the search terms "pregabalin" and "thrombocytopenia" yielded no published cases. The patient's other medications were ruled out, as she had been on her current regimen for 5 years. Viral and bacterial infections causing thrombocytopenia may be acute (e.g., rubella, infectious mononucleosis, ehrlichiosis, hepatitis) or chronic and persistent (e.g., HIV infection).⁵ In this case, the platelet count had shown signs of recovery before the initiation of ceftriaxone, which suggests that the thrombocytopenia was probably not due to infection. Myelodysplastic syndrome and mixed connective tissue disease were excluded, because the antinuclear antibody, rheumatoid factor, and serum protein electrophoresis results were normal, and the platelet count increased after discontinuation of pregabalin. Idiopathic thrombocytopenic purpura was unlikely, as the platelet count had increased to $184 \times 10^9/L$ before the prednisone was started.

There are 2 other possible explanations for the exacerbation of the patient's symptoms on day 2 of the admission. The retrosternal chest pain, shortness of breath, and anxiety might have been related to the patient's tachycardia, which, along with palpitations, may occur in up

*The patient and her family gave verbal consent to publish this letter.



to 10% of patients treated with salbutamol.⁶ After the patient was admitted to hospital, salbutamol 2.5 mg and ipratropium 500 µg were administered every 4 h by nebulizer. Once the salbutamol was discontinued and the dose of ipratropium was decreased to 250 µg every 4 h, there was no further tachycardia. Another important factor was the patient's inability to speak English; she was therefore unable to communicate with the staff, which probably exacerbated her anxiety and shortness of breath.

The slight toxic changes seen in the neutrophils on the peripheral blood smear at the time of admission and the increase in white blood cell count on day 2 might have been related to the urinary tract infection and possible exacerbation of COPD. The patient's C-reactive protein was also elevated. C-reactive protein is an acute-phase reactant and is a sensitive but nonspecific indicator of acute injury, bacterial infection, and inflammation.⁷ In the case reported here, the elevated C-reactive protein might have been due to infection. After discontinuation of pregabalin and before initiation of ceftriaxone, the platelet count had increased from $23 \times 10^9/L$ to $82 \times 10^9/L$ within 42 h. This implies that infection was less likely the cause of the thrombocytopenia. The exclusion of other potential causes and the onset of and recovery from thrombocytopenia suggest a probable relationship to pregabalin.

References

1. Aster RH, Bougie DW. Drug-induced immune thrombocytopenia. *N Engl J Med* 2007;357(6):580-587.
2. Visentin GP, Liu CY. Drug-induced thrombocytopenia. *Hematol Oncol Clin N Am* 2007;21(4):685-696.
3. Lyrica product monograph. Vega Baja (PR): Pfizer Pharmaceuticals LLC. 2007 Jun.
4. Naranjo CA, Busto U, Sellers EM, Sandor P, Ruiz I, Roberts EA, et al. A method for estimating the probability of adverse drug reactions. *Clin Pharmacol Ther* 1981;30(2):239-245.
5. George JN. Clinical manifestations and diagnosis of immune (idiopathic) thrombocytopenic purpura in adults. In: *UpToDate online, version 16.1* [Internet database]. Waltham (MA): UpToDate Inc; [updated 2007 Dec 20; cited 2008 May 28]. Available from: <http://www.uptodateonline.com>. Subscription required to access content.
6. Albuterol (drug evaluation). In: Klasco RK, editor. *DRUGDEX® System* [Internet database]. Greenwood Village (CO): Thomson Healthcare; [cited 2008 Jun 3]. Available from: <http://www.thomsonhc.com>
7. C-reactive protein. In: *Lexi-Comp Online. Lab tests and diagnostic procedures* [Internet]. Hudson (OH): Lexi-Comp, Inc; c1978-2008 [cited 2008 Jul 8]. Available from: <http://online.lexi.com/crlonline?siteid=1>. Subscription required to access content.

Duane Bates, BScPharm, ACPR
Clinical Practice Leader, Medicine
Department of Pharmacy

Scott Kirby, BSc, BScPharm
Clinical Pharmacist Hospitalist Service
Department of Pharmacy

Andries Louw, MD, CCFP
Hospitalist Physician
Department of Family Medicine
Peter Lougheed Centre
Calgary, Alberta